

Revision Arthroscopic Shoulder Instability Repair

R. Alexander Creighton, M.D., Anthony A. Romeo, M.D.,
Fredrick M. Brown, Jr., R.N., M.S., Jennifer K. Hayden, R.N., and Nikhil N. Verma, M.D.

Purpose: The purpose of this study was to report on a difficult patient population and to critically evaluate the role of revision arthroscopic stabilization surgery. **Methods:** Eighteen patients with failed traumatic instability repairs were treated with revision arthroscopic labral fixation and plication with a mean follow-up of 29.7 months (range, 24 to 48 months). There were 15 male patients and 3 female patients with a mean age of 28.6 years (range, 15 to 50 years). Of the 18 patients, 9 were Workers' Compensation cases. The 18 patients had a mean of 1.55 surgeries before our revision surgery, with 9 having a component of thermocapsular shrinkage. The patients' characteristics, operative techniques, and findings were recorded, and their clinical outcome was critically evaluated (via physical examination, visual analog pain scale, Simple Shoulder Test, American Shoulder and Elbow Surgeons score, and Short Form 12). **Results:** The revision surgery incorporated a 4-portal technique via a mean of 4.6 suture anchors and 3 plication stitches, and 15 patients received a rotator interval closure. At the follow-up evaluation, 13 patients had satisfactory results whereas 5 cases were considered clinical failures (with recurrent instability in 3 and pain in 2). There was clinically significant improvement in pain score (6 preoperatively ν 2 postoperatively, $P = .0001$), Simple Shoulder Test score (6 preoperatively ν 10 postoperatively, $P = .001$), and American Shoulder and Elbow Surgeons score (50 preoperatively ν 76 postoperatively, $P = .001$). Of the 9 Workers' Compensation patients, 5 were able to return to their original work. **Conclusions:** Arthroscopic revision instability repair by use of a combination of suture anchors, plication stitches, and rotator interval closure can result in a satisfactory outcome in selected patients. **Level of Evidence:** Level IV, therapeutic case series. **Key Words:** Shoulder—Instability—Revision—Arthroscopic.

Recurrent instability after operative intervention for traumatic unidirectional anterior shoulder instability is a difficult problem for both the patient and treating physician. Whereas recurrence rates for open surgery have been reported as less than 10%, the results from arthroscopic treatment are more variable,

ranging from 0% to 43%.¹⁻⁶ Treatment options for failed shoulder instability repair include conservative care with physical therapy, bracing and activity modifications, and revision surgical intervention. Revision surgery of failed shoulder instability repair has been addressed with open procedures with failure rates ranging from 8% to 39%.⁷⁻¹² To our knowledge, the clinical outcome of revision arthroscopic surgery for failed instability repair of the shoulder is not well known. In fact, there is only 1 clinical study on this topic in the literature.¹³ The purpose of this study was to report our experience with this difficult patient population and to critically evaluate the outcome of our arthroscopic technique in revision cases. Our hypothesis was that arthroscopic techniques would have similar results with regard to elimination of instability when compared with more traditional open techniques.

From the Department of Orthopaedics, The University of North Carolina (R.A.C.), Chapel Hill, North Carolina, and Midwest Orthopaedics at Rush, Rush University Medical Center (A.A.R., F.M.B., J.K.H., N.N.V.), Chicago, Illinois, U.S.A.

Dr. Romeo has a consulting relationship with Arthrex, Naples, Florida. The other authors report no conflict of interest. Research was performed at Midwest Orthopaedics at Rush.

Address correspondence and reprint requests to R. Alexander Creighton, M.D., Department of Orthopaedics, The University of North Carolina at Chapel Hill, 3134 Bioinformatics Bldg, Chapel Hill, NC 27599-7055, U.S.A. E-mail: alex_creighton@med.unc.edu

*© 2007 by the Arthroscopy Association of North America
0749-8063/07/2307-6180\$32.00/0*

doi:10.1016/j.arthro.2007.01.021

METHODS

Patient Selection

The operative logs of the senior author were reviewed over a 3-year period (1999 to 2002) to identify patients with a minimum 2-year follow-up. During that period of data collection, the senior author performed 50 primary arthroscopic instability repairs yearly, on average, and it was during this period that he began to exclusively perform arthroscopic procedures for traumatic instability. Inclusion criteria included previous traumatic anterior instability treated by open or arthroscopic stabilization with recurrent symptoms of instability (either subluxation or dislocation). Exclusion criteria included patients with large bony defects (>25% bone loss of the glenoid) requiring open reconstruction with a Latarjet procedure (6 total during the same period of data collection) and patients with multidirectional or posterior instability.^{12,14,15} Eighteen patients who met the inclusion criteria for this study were identified. There were 15 male patients and 3 female patients with a mean age of 28.6 years (range, 15 to 50 years). Of the 18 patients, 9 were Workers' Compensation cases. The 18 patients had a mean of 1.55 surgeries (range, 1 to 3) before revision, with 9 having a component of thermal shrinkage. The mean time from the primary stabilization to recurrent instability was 10 months (range, 4 to 20 months). Eight patients had recurrent dislocations, whereas ten had symptomatic recurrent subluxations. The right extremity was involved in 10 patients and the left in 8. The dominant extremity was involved in 9 patients.

All patients were treated with revision arthroscopic labral fixation and capsular plication with a mean follow-up of 29.7 months (range, 24 to 48 months). Data collection was approved by the patients and the institutional review board at our institution. A retrospective chart review was performed, and data regarding patient demographics, previous surgical procedures, and recurrent instability events were collected. The patients' preoperative data were collected at the preoperative appointment before the day of surgery. The operative report of the revision surgical procedure was reviewed to determine the number of anchors and plication sutures used, as well as the inclusion of rotator interval closure. Once patients were identified, they were contacted and a follow-up visit was scheduled. Patients were asked to complete a visual analog pain scale, Simple Shoulder Test (SST), American Shoulder and Elbow Surgeons (ASES) shoulder score,

and Short Form 12 (SF-12) (both physical and mental components). Patients were also asked whether they had any recurrence of instability, either subluxation or dislocation, since the time of the revision procedure. Finally, the 9 Workers' Compensation patients were asked about their ability to return to their preinjury level of work.

Surgical Technique

Examination with the patient under anesthesia was performed in the supine position. Range of motion was recorded, as was humeral translation in the anterior, inferior, and posterior directions, and compared with that of the contralateral limb. The translation in the anterior and posterior direction was rated as grade 0 (glenoid face), grade I (to the glenoid rim), grade II (over the glenoid rim), and grade III (dislocation without spontaneous reduction). Inferior translation was evaluated by use of the inferior sulcus sign. The sulcus sign was given a grade of 0 (no sulcus sign), I (<1 cm), II (1 to 2 cm), or III (>2 cm).¹⁶

The patient was then positioned in the lateral decubitus position on a beanbag, and the operative extremity was placed in a commercially available traction device. The shoulder was abducted approximately 50° and flexed 15° via a 10-lb weight, and a strap was placed in the axilla, also loaded with about 10 lb. The described procedure is for a right shoulder. Diagnostic arthroscopy was performed through standard posterior and anterosuperior portals. Attention was paid to evaluate bone loss of the anteroinferior glenoid and posterolateral defects of the humeral head. The arthroscope was placed in the anterosuperior portal to view the anterior glenoid to rule out an inverted-pear glenoid as described by Burkhart and colleagues^{14,15} (Fig 1). In addition, in cases that had a component of prior thermal treatment, the capsule was critically evaluated. If defects of the glenoid and humeral head were not significant and the capsule was adequate, the decision was made to proceed with arthroscopic revision stabilization. (Over the data collection time period, 6 arthroscopic procedures were abandoned to perform Latarjet procedures.) An 18-gauge spinal needle was used to first establish a 5-o'clock portal while looking from the posterior portal, just above the superior aspect of the subscapularis or 5 to 10 mm inferior to the superior rolled edge of the subscapularis. An 8.25-mm clear cannula was placed into this area after sequential dilating over a switching stick. With the arthroscope in the anterosuperior portal, a 7-o'clock portal was established, which was obtained

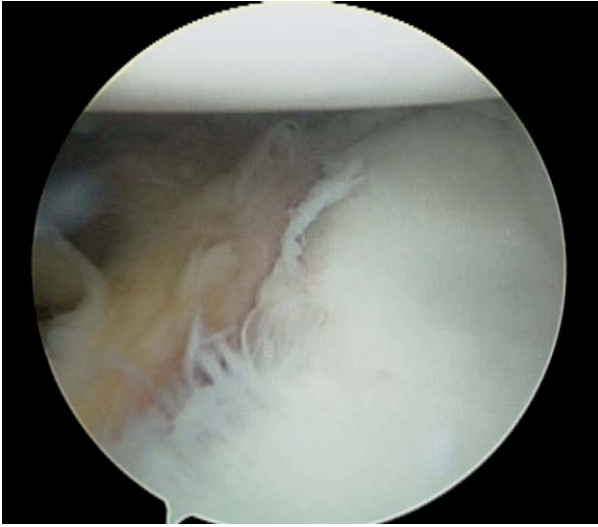


FIGURE 1. Arthroscopic image of inverted-pear glenoid.

from the posterolateral aspect of the shoulder, approximately 2 cm lateral and 1 cm inferior to the standard posterior portal. An 18-gauge needle was used followed by sequential dilation over a switching stick and placement of an 8.25-mm clear cannula. We believe that the establishment of both the 5- and 7-o'clock portals facilitates placement of anchors and also improves the ease of instrumented capsulolabral plication.^{17,18}

At that point, the labrum was mobilized from the anteroinferior neck of the glenoid. With the arthroscope in the anterosuperior portal, an elevator was used from the 5-o'clock portal to free up the labrum. Visualization from the anterosuperior portal ensured adequate labrum preparation. Next, the edge of the glenoid bony surface was debrided with a shaver and a bur to remove the fibrous tissue off of the neck of the glenoid and prepare a bleeding bony bed to aid in healing of the labrum to the glenoid. An arthroscopic rasp was used to gently incite a bleeding/inflammatory response in the shoulder capsule, including the area around the inferior glenohumeral ligament.

Attention was then drawn to the repair. We chose to first perform a capsulolabral plication posteriorly/inferiorly, which was done in all of our cases of revision shoulder stabilization. The arthroscope was switched back to the posterior portal, and by use of a suture passer through the 7-o'clock portal, a capsulolabral plication repair was performed starting at the 7-o'clock position. Capsular plication of approximately 1 cm was performed between the 7- and 6-o'clock positions with the suture passer, which was

then advanced through the intact posterior/inferior labrum at the glenoid-labrum interface. The No. 1 monofilament suture was shuttled out of an anterior alternate cannula and then switched for a No. 2 braided permanent suture by tying them together and pulling the monofilament back out of the 7-o'clock portal. Our capsulolabral plication was completed by performing a sliding knot of the No. 2 braided permanent suture through the 7-o'clock portal. These plication stitches were tied from back to front so that the view of the sliding knots would not be inhibited.

Next, the anterior anchor repair was performed. With the arthroscope in the posterior portal, the first Bio-SutureTak (Arthrex, Naples, FL) was placed at the 5:30 position on the glenoid, approximately 2 mm onto the articular rim through the 5-o'clock portal. Once the anchor was placed, the suture passer was used from the 5-o'clock portal to obtain a capsulolabral repair, again taking approximately 1 cm of capsular tissue; however, the exact amount was based on the amount of capsular laxity encountered during the case. The repair was continued up the face of the glenoid, placing suture anchors approximately 5 to 7 mm apart by use of the suture passer, through the 5-o'clock portal, to continue the reapproximation of labral/capsular tissue and superior shift onto the face of the glenoid articular surface. Once the labral/capsular tissue was repaired, a rotator interval closure was performed if this space was considered to be redundant or if the patient had a persistent sulcus examination in external rotation (Fig 2).

Rehabilitation Protocol

All of the repairs were performed on an outpatient basis. For the first 4 weeks, a shoulder immobilizer is worn at all times, except during hygiene activities and therapeutic exercises. During the first 4 weeks, passive exercises with 90° of forward elevation, 45° of abduction, 20° of external rotation, and internal rotation to the stomach are performed. After 4 weeks, prone extensions and scapular stabilizing exercises are begun, with increases in forward elevation to 140°, external rotation to 40°, and abduction to 60°, as well as internal rotation behind the back to the waist. At 8 weeks, the patient should progress to full active motion without discomfort, with gentle passive stretching at the end ranges of motion, Thera-Band (The Hygenic Corporation, Akron, OH) exercises, advancing to weights, and exercises including the rotator cuff, deltoid, and scapular musculature. After 12 weeks, the patient begins functional progression to work- and

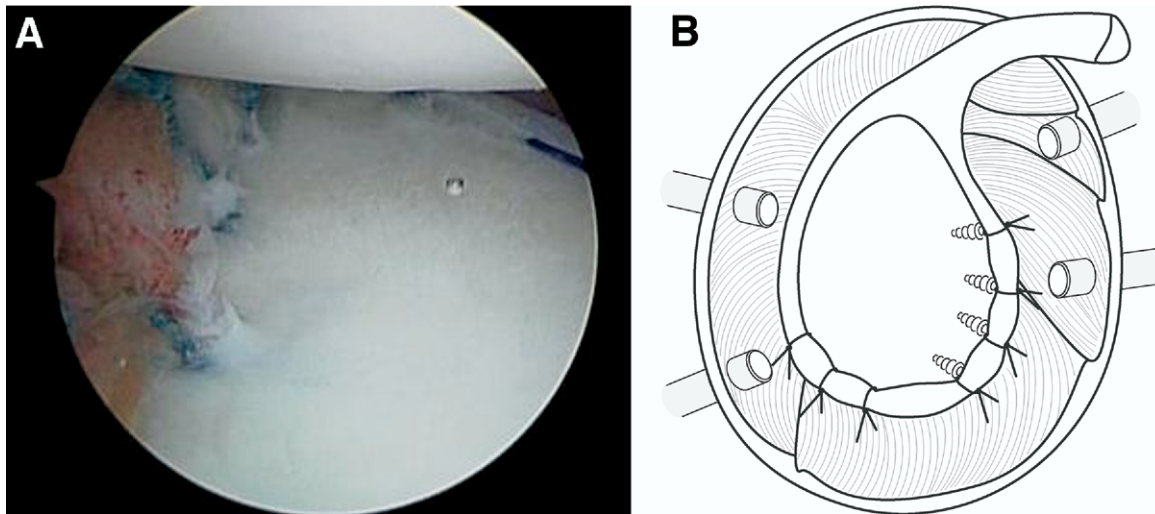


FIGURE 2. (A) Arthroscopic image of final repair. (B) Drawing of final repair.

sports-related activities and advanced weight training. At 6 months after surgery, the patient is allowed to proceed with all work and sports demands.

Statistical Analyses

Statistical analyses were performed by use of the SPSS program (SPSS, Chicago, IL), with statistical significance being set at $P = .05$. We used the following nonparametric tests: Mann-Whitney, Wilcoxon signed rank, and Kruskal-Wallis.

RESULTS

With regard to revision surgical technique, all patients were noted to have recurrent anterior-inferior labral tears at the time of surgery. On the basis of a circle concept of 360° , the mean degree of labral/capsular injury was 155° (range, 100° to 225°). Labral repair included, on average, 4 suture anchors (range, 3 to 6) and 3 plication stitches (range, 1 to 4), and 15 of 18 patients received a rotator interval closure.

With regard to the ASES score, good and excellent results were found in 13 patients (72%). The ASES score improved from 50 preoperatively to 76 postoperatively ($P = .001$). The pain score on the visual analog scale improved from 6 before surgery to 2 after surgery ($P = .001$). The SST score improved from 6 before surgery to 10 after surgery ($P = .001$). We found no clinically significant changes with regard to the SF-12, strength, prior thermal treatment, or motion, except for external rotation. A mean loss of

external rotation of 5° at the side was found after surgery (Table 1).

Of the 9 Workers' Compensation patients, 5 (55%) were able to return to their previous level of work. Comparison between our Workers' Compensation patient population and our non-Workers' Compensation patient population yielded interesting findings, with statistically significant differences between the groups (Table 2).

DISCUSSION

The purpose of this report was to analyze a difficult patient population with failed traumatic anterior instability surgery. To date, there has only been 1 report on the outcome of revision arthroscopic stabilization surgery.¹³ Traditionally, failed shoulder instability repair has been addressed with open procedures with many variations of capsular shifts and bony augmentations.^{7-10,12,14,19} The success rates of these procedures are quite variable and range from 50% to 92%. Kim et al.¹³ were able to address recurrent instability with an arthroscopic technique that led

TABLE 1. Results of Statistically Significant Findings

Evaluation	Preoperative	Postoperative	<i>P</i> Value
Visual analog scale	6	2	$P = .0001$
SST	6	10	$P = .001$
ASES	50	76	$P = .001$

TABLE 2. Comparison of Workers' Compensation and Non-Workers' Compensation Patients

Evaluation	Workers' Compensation	Non-Workers' Compensation	P Value
Age	35 yr	22 yr	$P = .01$
Visual analog scale			
Preoperative	7	4	$P = .01$
Postoperative	3	1	$P = .015$
SST			
Preoperative	4	8	$P = .02$
Postoperative	9	11	$P = .05$
ASES			
Preoperative	32	65	$P = .01$
Postoperative	67	87	$P = .04$

to results that were comparable to those of open procedures. Their success rate of producing a stable shoulder was 78%. The Rowe score in their patients improved from 87 to 91, and the SST score improved from 8 to 11. Their 5 clinical failures with recurrent instability were correlated to contact sports.

We had 5 cases of clinical failure, 3 related to recurrent instability and 2 related to pain. We believe that our patient population was slightly more challenging than that of Kim et al.¹³ because our patients had more prior surgeries (mean, 1.55; range, 1 to 3), 50% had a thermal component, and 50% were Workers' Compensation patients. Our rate of instability failure (3/18 [17%]) compares with that of Kim et al. and with the traditional open techniques.^{7,9,10,12,14} Two of the instability repair failures included recurrent subluxation associated with a traumatic episode. In the first patient, this episode occurred when he hopped a fence when running from a dog while delivering pizza 6 weeks after surgery. In the other patient, the episode occurred when he fell off of a skateboard 13 months after surgery. Despite these subluxation episodes, both patients are satisfied with the overall result of their surgery. The other patient in whom instability repair failure occurred had a frank dislocation when he fell at a construction site 8 months after arthroscopic surgery. He has since undergone an open Latarjet procedure. One of the failures related to pain was associated with humeral head arthritis caused by a prominent metal anchor from a previous open surgery. In the other patient who had continued pain, this was related to axillary nerve paresthesia from a previous arthroscopic thermal procedure. Despite these patients' pain issues, both believe that the instability in their shoulders has improved and they would undergo surgery again for that reason.

Although the data were interesting, we do not believe any true conclusions can be drawn from the Workers' Compensation patient population in our study. Nicholson²⁰ showed that arthroscopic acromioplasty consistently provided a good surgical outcome and the ability to return to work in both Workers' Compensation and non-Workers' Compensation populations. The only difference was that the Workers' Compensation population took an extra 4 weeks to return to full duty. In our study there were significant differences in the age of the patients, with the Workers' Compensation group being 13 years older. In addition, both of our failures related to pain were in the Workers' Compensation group, potentially skewing our data because of the small numbers.

There are some important points with regard to surgical technique that we believe are important when performing revision cases. Although the traditional lesion of traumatic anterior instability is considered the Bankart lesion, with labral tearing from the 3-o'clock to 6-o'clock position (right shoulder) or 90° based on the circle concept, we believe that a significant amount of the energy of injury is also dissipated into the inferior and posterior-inferior soft tissues, given that the mean degree of injury in our study was 155° (range, 100° to 225°). This is because dislocation occurs in an anterior-inferior direction, not a straight anterior direction. Both McFarland et al.²¹ and Rodeo et al.²² have shown capsular changes after shoulder dislocations and surgical treatment. Subsequently, we believe that placing capsular plication sutures in the inferior and posterior-inferior capsular tissue is important to eliminate a redundant inferior capsular pouch and minimize recurrence rates. We believe that our technique of arthroscopic shoulder stabilization allows this to be accomplished with the use of 5-o'clock and 7-o'clock portal positions to appropriately address the posterior and inferior pathology. Finally, we used rotator interval closure in almost all cases ($n = 15$) to further decrease capsular volumes. Despite the use of this aggressive type of capsular plication, we have not seen significant problems with motion loss after surgery (5° loss of external rotation at the side).

Although we believe that an all-arthroscopic technique can be used in almost all cases of recurrence resulting from soft-tissue pathology, it is important to recognize that bony defects are also an important cause of recurrent instability and should be addressed by use of open techniques of bone reconstruction. Burkhart and De Beer¹⁴ had a 67% instability recurrence rate when arthroscopic Bankart repairs were performed in patients with significant bone loss. Lo

et al.¹⁵ found that the mean amount of bone loss in cadaveric specimens to convert a normal pear-shaped glenoid into an inverted-pear glenoid was 7.5 mm (range, 6.5 to 9.0 mm), representing 28.8% of the glenoid width (range, 27% to 30%). We use an estimation of 25% bone loss off of the glenoid or engagement of the Hill-Sachs lesion in an abducted, externally rotated position as the criterion to abandon an arthroscopic procedure and convert to an open procedure. During the same time period as this study, we aborted 6 arthroscopic stabilization procedures and converted to Latarjet procedures to address the bony pathology. Warner et al.¹² described another option in patients with bone loss—fixation of autogenous tricortical iliac crest bone graft to the glenoid—and found initially encouraging results. Other causes of failure after primary and revision instability repairs in the literature include patient age, large Hill-Sachs lesion, contact sports, poor soft-tissue envelope, arthritic changes, and operative technical errors.^{19,23-29}

There are several weaknesses to this study. First, the sample size is extremely limited. However, the patient population with recurrent instability after operative procedures is small, and larger numbers would likely require multicenter evaluation. Second, this is a retrospective case series with no control group of patients with recurrent instability treated nonoperatively or treated with open revision for comparison. Finally, the follow-up period is relatively short, and follow-up will need to be continued. Manta et al.³⁰ showed that failure rates increased when follow-up was continued from 2 to 5 years.

CONCLUSIONS

Arthroscopic revision instability repair can provide stability in slightly greater than 80% of patients in a carefully selected patient population. Arthroscopic labral/capsular repair in a revision setting can be performed with a 4-portal technique. Preoperatively, it is important to recognize factors that may not be improved with revision stabilization, such as arthritic and nerve-type pain.

REFERENCES

- Guanche CA, Quick DC, Sodergren KM, Buss DD. Arthroscopic versus open reconstruction of the shoulder in patients with isolated Bankart lesions. *Am J Sports Med* 1996;24:144-148.
- Geiger DF, Hurley JA, Tovey JA, Rao JP. Results of arthroscopic versus open Bankart suture repair. *Clin Orthop Relat Res* 1997:111-117.
- Steinbeck J, Jerosch J. Arthroscopic transglenoid stabilization versus open anchor suturing in traumatic anterior instability of the shoulder. *Am J Sports Med* 1998;26:373-378.
- Cole BJ, L'Insalata J, Irrgang J, Warner JJ. Comparison of arthroscopic and open anterior shoulder stabilization. A two to six-year follow-up study. *J Bone Joint Surg Am* 2000;82:1108-1114.
- Kim SH, Ha KI, Kim SH. Bankart repair in traumatic anterior shoulder instability: Open versus arthroscopic technique. *Arthroscopy* 2002;18:755-763.
- Fabbriciani C, Milano G, Demontis A, Fadda S, Zirano F, Mulas PD. Arthroscopic versus open treatment of Bankart lesion of the shoulder: A prospective randomized study. *Arthroscopy* 2004;20:456-462.
- Rowe CR, Zarins B, Ciullo JV. Recurrent anterior dislocation of the shoulder after surgical repair. *J Bone Joint Surg Am* 1984;66:159-168.
- Yee AJ, Devane PA, Horne G. Surgical repair for recurrent anterior instability of the shoulder. *Aust N Z J Surg* 1999;69:802-807.
- Zabinski SJ, Callaway GH, Cohen S, Warren RF. Revision shoulder stabilization: 2- to 10-year results. *J Shoulder Elbow Surg* 1999;8:58-65.
- Levine WN, Arroyo JS, Pollock RG, Flatow EL, Bigliani LU. Open revision stabilization surgery for recurrent anterior glenohumeral instability. *Am J Sports Med* 2000;28:156-160.
- Jolles BM, Pelet S, Farron A. Traumatic recurrent anterior dislocation of the shoulder: Two- to four-year follow-up of an anatomic open procedure. *J Shoulder Elbow Surg* 2004;13:30-34.
- Warner JJ, Gill TJ, O'hollerhan JD, Pathare N, Millett PJ. Anatomical glenoid reconstruction for recurrent anterior glenohumeral instability with glenoid deficiency using an autogenous tricortical iliac crest bone graft. *Am J Sports Med* 2006;34:205-212.
- Kim SH, Ha KI, Kim YM. Arthroscopic revision Bankart repair: A prospective outcome study. *Arthroscopy* 2002;18:469-482.
- Burkhart SS, De Beer JF. Traumatic glenohumeral bone defects and their relationship to failure of arthroscopic Bankart repairs: Significance of the inverted-pear glenoid and the humeral engaging Hill-Sachs lesion. *Arthroscopy* 2000;16:677-694.
- Lo IK, Parten PM, Burkhart SS. The inverted pear glenoid: An indicator of significant glenoid bone loss. *Arthroscopy* 2004;20:169-174.
- Altchek DW, Warren RF, Skyhar MJ, Ortiz J. T-plasty modification of the Bankart procedure for multidirectional instability of the anterior and inferior types. *J Bone Joint Surg Am* 1991;73:105-112.
- Davidson PA, Tibone JE. Anterior-inferior (5 o'clock) portal for shoulder arthroscopy. *Arthroscopy* 1995;11:519-525.
- Davidson PA, Rivenburgh DW. The 7-o'clock posteroinferior portal for shoulder arthroscopy. *Am J Sports Med* 2002;30:693-696.
- Young DC, Rockwood CA Jr. Complications of a failed Bristow procedure and their management. *J Bone Joint Surg Am* 1991;73:969-981.
- Nicholson GP. Arthroscopic acromioplasty: A comparison between workers' compensation and non-workers' compensation populations. *J Bone Joint Surg Am* 2003;85:682-689.
- McFarland EG, Kim TK, Banchasuek P, McCarthy EF. Histologic evaluation of the shoulder capsule in normal shoulders, unstable shoulders, and after failed thermal capsulorrhaphy. *Am J Sports Med* 2002;30:636-642.
- Rodeo SA, Suzuki K, Yamauchi M, Bhargava M, Warren RF. Analysis of collagen and elastic fibers in shoulder capsule in patients with shoulder instability. *Am J Sports Med* 1998;26:634-643.

23. Gill TJ, Micheli LJ, Gebhard F, Binder C. Bankart repair for anterior instability of the shoulder. Long-term outcome. *J Bone Joint Surg Am* 1997;79:850-857.
24. Grana WA, Buckley PD, Yates CK. Arthroscopic Bankart suture repair. *Am J Sports Med* 1993;21:348-353.
25. Hovelius L, Augustini GBG, Predin OH, Jahansson MO, Norin KR, Thorling J. Primary anterior dislocation of the shoulder in young patients. *J Bone Joint Surg Am* 1996;78:1677-1684.
26. Mazocco AD, Brown FM, Carreira DS, Hayden J, Romeo AA. Arthroscopic anterior shoulder stabilization of collision and contact athletes. *Am J Sports Med* 2005;33:52-60.
27. Meehan RE, Petersen SA. Results and factors affecting outcome of revision surgery for shoulder instability. *J Shoulder Elbow Surg* 2005;14:31-37.
28. Pagnani MJ, Warren RF, Altchek DW, Wickiewicz TL, Anderson AF. Arthroscopic shoulder stabilization using transglenoid sutures. A four-year minimum follow-up. *Am J Sports Med* 1996;24:459-467.
29. Wirth MA, Blatter G, Rockwood CA Jr. The capsular imbrication procedure for anterior instability of the shoulder. *J Bone Joint Surg Am* 1996;78:246-259.
30. Manta JP, Organ S, Nirschl RP, Pettrone FA. Arthroscopic transglenoid suture capsulolabral repair: Five-year follow-up. *Am J Sports Med* 1997;25:614-618.